

Giant Cell Lesion of the Jaw: A Case Report in a Child

MK Gupta, *SG Naidu, *VJ Maheshwari

Department of Oral & Maxillofacial Surgery, *Oral Medicine & Radiology, People's Dental Academy, Peoples' Campus Bhanpur, Bhopal-462037

Abstract:

Giant cell lesions of the jaw include cherubism, central giant cell granuloma (CGCG) peripheral giant cell granuloma (PGCG) aneurysmal bone cyst, traumatic bone cyst and jaw tumour of hyperparathyroidism. The histological, radiographic and clinical diagnosis is particularly difficult in these types of lesions due to their variable clinical behavior and identical histological presentation with abundant giant cells. We present the case of a 12-year-old boy, who developed a painless swelling of approximately 4 cm, in the left angle of the mandible. The lesion demonstrated slow, progressive and continuous growth. The patient was surgically treated by a conservative approach. The histopathology confirmed the suspected diagnosis of central giant cell granuloma.

Key words: Giant cell, Reparative granuloma, CGCG

Introduction:

There are a number of lesions that occur in the jaws that contain giant cells within them. They include cherubism, giant cell granuloma of the jaws, giant cell tumour, aneurysmal bone cyst, traumatic bone cyst and jaw tumour of hyperparathyroidism. Their relationship to each other, however, is ill defined. The histological similarities cease with the finding of multinucleated giant cells of osteoclastic origin (Liu et al, 2003) and the lesions themselves greatly differ in their genetic origin, etiopathogenesis and clinical behaviour.

The central giant cell granuloma (CGCG) of the jaws accounts for approximately 7% of all benign tumors of the jaws (Kramer et al, 1991). The CGCG may occur at any age, but it is most commonly seen in the first 3 decades. 37.5% of CGCGs are located in the incisor, canine, and premolar regions of the mandible (Kaffe et al, 1996). CGCG of the jaw is usually unifocal and have traditionally been treated surgically; the common therapy being curettage or resection (Kermer et al, 1994; Eisenbud et al, 1988). We present a case of a central giant cell granuloma in a child patient who was managed by a conservative surgical approach.

Case report 1:

A 12 year-old boy reported to the Department of Oral Medicine and Radiology, People's Dental Academy with a swelling in the left angle of the

mandible of one year duration. The swelling had remained asymptomatic while gradually enlarging to cause the facial disfigurement evident at the time of presentation. No history of trauma was elicited nor any systemic or local infections. The boy along with a twin was the eldest child of 4 siblings borne of a non-consanguineous marriage. The prenatal history was unremarkable and delivery was at full term and normal. There was no history of similar disease in any of the siblings or the parents of the affected child. A physical examination revealed a moderately built and nourished male with no known systemic disorder. A facial asymmetry due to a poorly defined solitary swelling in the left angle of the mandible measuring 3x4 cms was noted (Fig.I). The overlying skin appeared normal, while

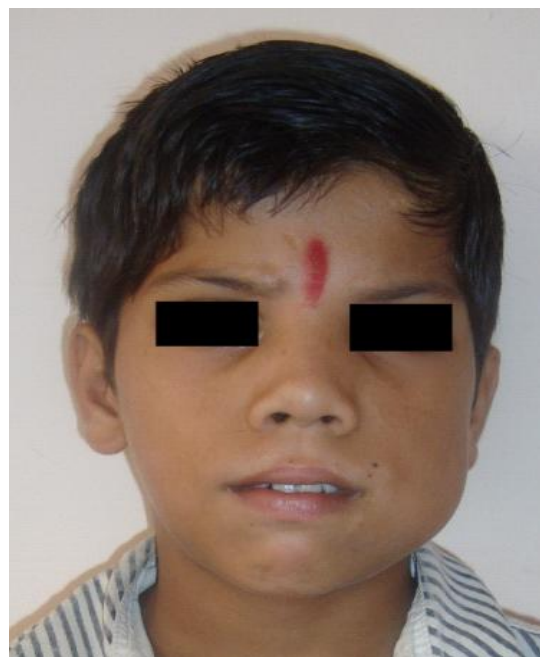

Fig. I: Extraoral Swelling in left angle of mandible.

Corresponding Author: Dr. M.K. Gupta, Prof. & Head, Department of Oral and Maxillofacial Surgery, People's Dental Academy, People's Campus Bhanpur, Bhopal-462037

Phone No.: 9303129994, 0755-4005361

E-mail : mkgupta1101@yahoo.com

the swelling itself was bony hard and non tender to palpation. Intra oral examination showed a diffuse enlargement in the alveolar portion of the entire left mandibular teeth # 36, 37, 38 region with obliteration of the buccal vestibule in the same region. Teeth # 37 and 38 were clinically missing. Tooth displacement and mobility were not evident in the same quadrant. The overlying mucosa appeared normal.

The swelling was non tender and bony hard on palpation with some areas of fluctuance in the buccal aspect. The adjacent dentition and the oral mucosa did not reveal any abnormality. A tooth vitality test revealed normal pulpal response of the teeth in the same quadrant. A provisional diagnosis of dentigerous cyst was made with the differential diagnosis of ameloblastoma, central giant cell granuloma, odontogenic myxoma and fibrous dysplasia.

The radiographic examination with an orthopantomogram (Fig. III) revealed a solitary well defined multilocular radiolucent lesion in the region of left mandibular angle and ramus. The lesion measured 2 X4 cm extending to involve the left coronoid with distinct and sclerotic borders except in the region of the superior aspect. Multiple overlapping locules appearing as 'soap bubbles' were noted within the lesion along with an unerupted tooth follicle of permanent left mandibular second molar. The mandibular canal was inferiorly displaced while areas of root resorption were not present. The maxilla did not reveal any abnormalities. The radiographic features led us to consider a diagnosis of ameloblastoma or a

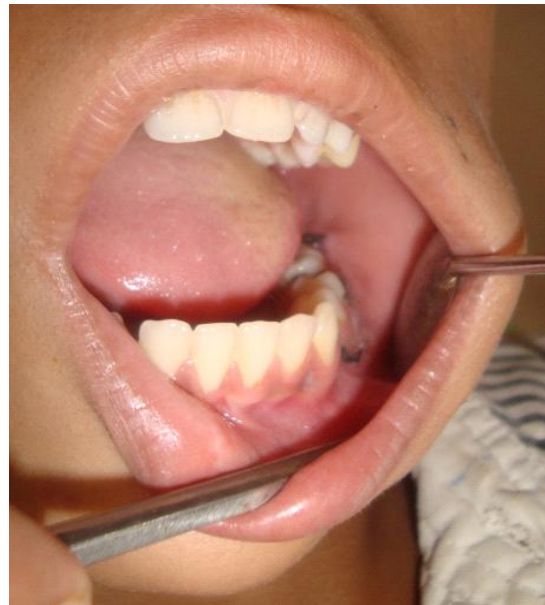

Fig. II: Intraoral photograph showing the site of surgery.

central giant cell granuloma. Ameloblastoma and central giant cell granuloma may appear unilocular or multilocular with a honeycomb or soap bubble appearance. Odontogenic myxoma may appear as a poorly defined or well-circumscribed radiolucent defect, which may be unilocular or multilocular with a tennis racquet appearance. Serum calcium, phosphorous and alkaline phosphatase levels were found to be normal thereby excluding brown tumour of hyperparathyroidism.

In view of the young age of the boy, a conservative surgery was performed under general

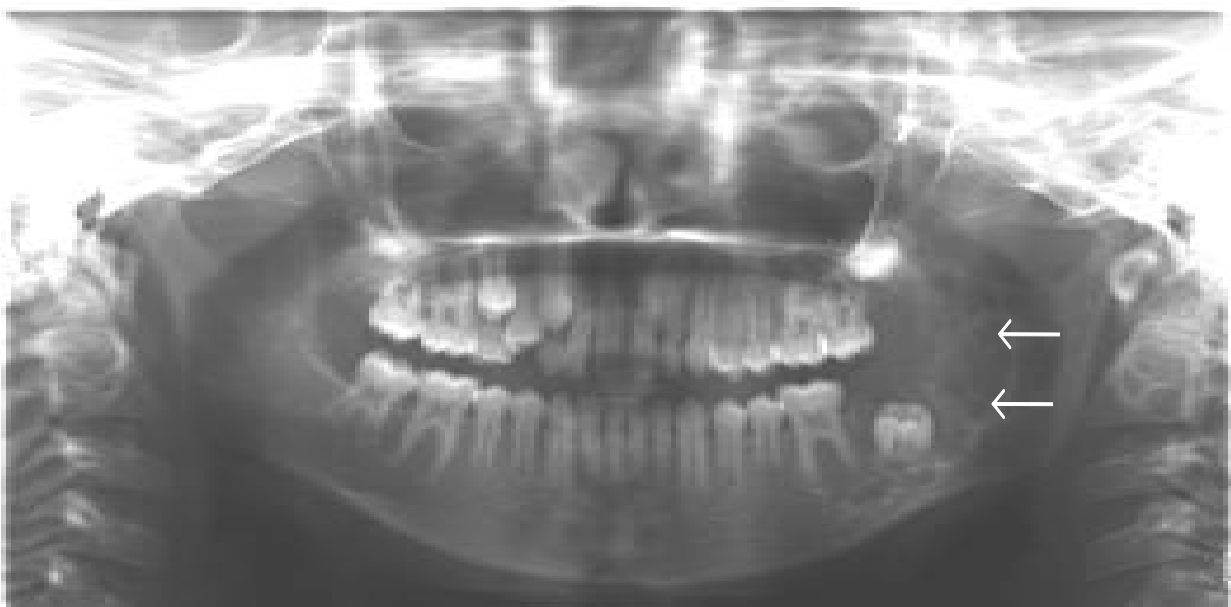


Fig. III: Panoramic radiograph showing multilocular radiolucent lesion with faint curved septae in left ramus-body of mandible.

anesthesia to spare the mandible with an aggressive curettage and marginal resection/peripheral osteotomy of the lesion. The unerupted permanent left mandibular second molar and the first molar were extracted during the procedure. The histopathological examination (Fig. IV) showed a highly vascularized fibrous stroma with several multinucleated giant cells with 20-30 nuclei. Randomly dispersed spindle shaped fibroblasts were also noted and a conclusive diagnosis of a central giant cell granuloma was made. The post surgical follow up (Fig. II & V) has remained uneventful till date.

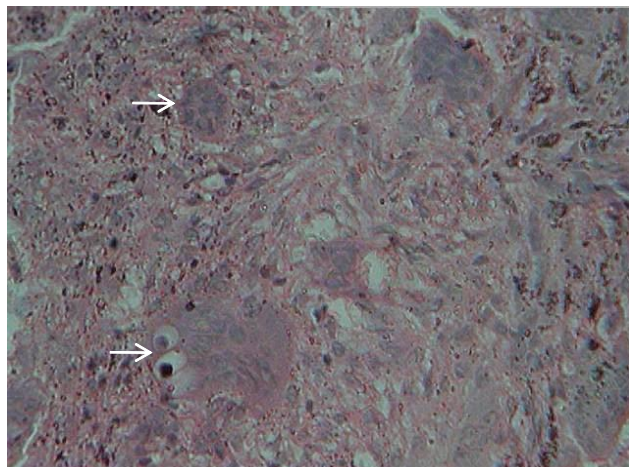


Fig. IV: Photomicrograph (H and E stain, magnification 40 x) showing multinucleated giant cells (~20 nuclei) and spindle shaped fibroblasts in a highly vascularized fibrous stroma.

Discussion:

Giant cell lesions of the jaws generally include cherubism, giant cell granuloma of the jaws, giant cell tumour (GCT), aneurysmal bone cyst, traumatic bone

cyst and jaw tumour of hyperparathyroidism. In 1953, Jaffe first described the “giant cell reparative granulomas” and distinguished them from the giant cell tumor that usually is found in the epiphyseal regions of long bones. He established two pathological entities in the jaws, the central giant cell granuloma (CGCG), arising within bone and the peripheral giant cell granuloma (PGCG) arising in soft tissue mass (Jaffe, 1953). Giant cell granuloma was described as an idiopathic non-neoplastic proliferative lesion and termed a reparative granuloma (Jaffe, 1953). Current consensus, however, is that these are not reparative lesions and that if they are not treated, they are progressive. The true nature of the central giant cell granuloma remains speculative. It has been suggested that it may be an inflammatory lesion, a reactive lesion, a true tumor, or an endocrine lesion (Pogrel, 2004). Expression of the c-Src gene has been implicated in the development of CGCG, GCT and cherubism (Wang et al, 2006). In addition, histologically identical lesions occur in patients with known genetic defects such as cherubism, Noonan syndrome, or neurofibromatosis type 1 (deLange et al, 2007). Central giant cell granuloma has been shown in a report to be further associated with a reciprocal translocation t (X; 4) (q22; q31.3) (Buresh et al, 1999).

Central giant cell granuloma is an uncommon lesion, usually asymptomatic and accounting for less than 7 % of all benign jaw lesions (Kramer et al, 1991). The lesion is found predominantly in children and young adults with more than 60% of all cases occurring before the age of 30 years (Kaffe et al, 1996). Lesions occur

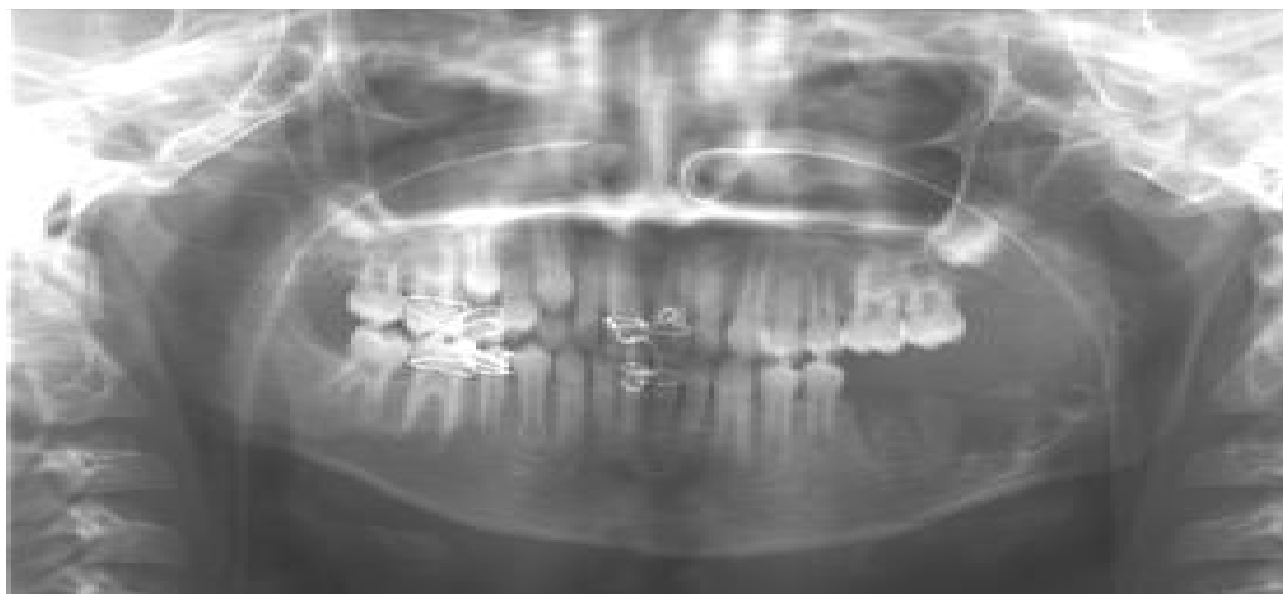


Fig. V: Post operative panoramic radiograph showing extracted tooth no 36 and 37 with area of resection.

more frequently in the mandible than in the maxilla in the anterior region of the jaws (Regezzi & Scuibba, 1989). Radiographically, CGCG presents as radiolucent defect, which may be unilocular or multilocular. The defect usually is well-circumscribed and, in some cases, displacement of teeth can be found (Chuong et al, 1986). Central giant cell granuloma is expansive in its growth; it does not grow around or invade nerve trunks. It also does not invade perineural sheaths or spread via perineural spaces. Histologically, CGCG contain focal arrangements of giant cells within a vascular stroma with thin-walled capillaries adjacent to the giant cells. There is a spindle cell stroma which may well be the cell of origin. The absence of perivascular cuffing (as seen in our case) can help differentiate CGCG from cherubism (Pogrel, 2004). Presence of foreign body type giant cell (as seen in our case and absence of stromal tumour cells differentiate CGCG from a GCT. 'Solid' aneurysmal bone cysts (ABC) are true benign neoplasms containing giant cells while trauma causing intramedullary hemorrhage has been implicated in the past as the etiology. Normal serum calcium, parathyroid hormone, alkaline phosphatase and phosphorous levels distinguish CGCG from other conditions like Brown tumour of hyperparathyroidism (Pogrel, 2004).

Cherubism is a self limiting condition, but giant cell granulomas can be aggressive with a tendency to recur and hence require treatment (Chuong et al, 1986). These lesions should be defined as "aggressive giant cell granulomas" of the jaws, rather than giant cell tumor (Ficarra et al, 1987). Giant cell tumour, on the other hand is aggressive with a high recurrence rate but also has a potential for malignant transformation (Hutter et al 1962). Aggressive/ recurring CGCG have a higher number and relative size index of giant cells and a greater fractional surface area occupied by giant cells (Chuong et al, 1986).

The conservative surgical treatment of CGCG usually involves curettage alone or alongwith peripheral ostectomy with no evidence of disease in a 2 year follow up period (Eisenbud et al, 1988). The margins of the CGCG may also be thermally sterilized with a laser or cryoprobes (Kermer et al, 1994). Radical surgical techniques of resection without continuity defect and peripheral ostectomy (Bataineh et al, 2002) and enbloc resection have sometimes been justified for aggressive CGCG (Chuong et al, 1986). However, recurrence with serious facial mutilation, loss of teeth and tooth germs seem unavoidable.

Paediatric patients necessitate conservative

management to prevent long term developmental defects. Steroids and calcitonin have been advocated in the recent past and they act by inhibition of osteoclastic activity. Equal parts of triamcinolone acetonide (10mg/ml) and 0.5% bupivacaine injected into the lesion for a period of 11 weeks has been shown to be effective in a child patient (Wendt et al, 2009). Relative contraindications do exist in certain medical conditions, such as diabetes mellitus, peptic ulcer, and generalized immunocompromised states. Calcitonin nasal spray 200 U/spray once or twice daily was reported to be safe and effective for the treatment of CGCG (Allon et al, 2009). But, therapy may be complicated owing to the great amount of discomfort and the relatively long duration of treatment, with poor compliance by children. Where surgery has been conservative daily subcutaneous interferon alpha (3 million units/m² of body surface area) has been tried as an adjuvant due to its anti-angiogenic properties; but significant side effects may limit its utility (Kaban et al, 2007). A combination of interferon alpha and imatinib given for 9 months has been shown to initiate regression of the lesion that continued after treatment had ceased (de Lange et al, 2009). Bisphosphonates have also been attempted intravenously with promising results (Davis et al, 1991). Nevertheless, recurrences of CGCG are not uncommon and can be seen in upto 46% of cases (Whitaker et al, 1993).

Conclusion:

Giant cell lesions occur frequently in children often showing aggressive behaviour. Our approach to conservatively manage the lesion has shown good results with regular follow up till date. In conclusion, giant cell lesions may present as a diverse group of conditions peculiar to the jaw bones but, their diagnosis and management in the pediatric patient still remains a challenge to the clinician.

Bibliography:

1. Allon DM, Anavi Y, Calderon S, Central giant cell lesion of the jaw: nonsurgical treatment with calcitonin nasal spray. *Oral Surgery, Oral Medicine, Oral Pathology Oral Radiology & Endodontics*, 2009;107(6):811-818.
2. Bataineh AB, Al-Khateeb T, Rawashdeh MA. The surgical treatment of central giant cell granuloma of the mandible. *Journal of Oral Maxillofacial Surgery*, 2002; 60(7): 756-776.

3. Buresh CJ, Seemayer TA, Nelson M, Neff JR, Dorfman HD, Bridge J. t (X;4) (q22;q31.3) in giant cell reparative granuloma. *Cancer Genetics & Cytogenet*, 1999; 115:80-81.
4. Chuong R, Kaban LB, Kozakewich H, Perez-Atayde A: Central giant cell lesions of the jaws: a clinicopathologic study. *Journal of Oral & Maxillofacial Surgery*, 1986;44(9):708-713.
5. Davis JP, Archer DJ, Fisher C, Wimalawansa SJ, Baldwin D, Wimalawansa SJ: Multiple recurrent giant cell lesions associated with a high circulating level of parathyroid hormone related peptide in a young adult. *British Journal of Oral & Maxillofacial Surgery*, 1991;29(2):102-105.
6. de Lange J, van den Akker HP, van den Berg H: Central giant cell granuloma of the jaw: a review of the literature with emphasis on therapy options. *Oral Surgery, Oral Medicine, Oral Pathology, Oral Radiology & Endodontics*, 2007;104(5):603-615.
7. de Lange J, van Rijn RR, van den Berg H, van den Akker HP: Regression of central giant cell granuloma by a combination of imatinib and interferon: a case report. *British Journal of Oral & Maxillofacial Surgery*, 2009;47(1):59-6.
8. Eisenbud L, Stern M, Rothberg M, Sach S: Central giant cell granuloma of the jaws: Experiences in the management of thirty-seven cases. *Journal of Oral and Maxillofacial Surgery*, 1988;46(5):376-384.
9. Ficarra G, Kaban LB, Hansen LS: Central giant cell lesions of the mandible and maxilla: A clinicopathologic and cytometric study. *Oral Surgery Oral Medicine and Oral Pathology*, 1987;49(1):64-44.
10. Hutter RVP, Worcester JB, Francis KC: Benign and malignant giant cell tumors of bone: A clinicopathological analysis of the natural history of the disease. *Cancer*, 1962;15(4):653-690.
11. Jaffe HL: Giant cell reparative granuloma, traumatic bone cyst, and fibrous (fibro-osseous) dysplasia of the jawbones. *Oral Surgery, Oral Medicine and Oral Pathology*, 1953;6(1):159-175.
12. Kaban LB, Troulis MJ, Wilkinson MS, Ebb D, Dodson TB: Adjuvant antiangiogenic therapy for giant cell tumors of the jaws. *Journal of Oral & Maxillofacial Surgery*, 2007;65(10):2018-2024.
13. Kaffe I, Ardekian L, Taicher S, Littner MM, Buchne A: Radiologic features of central giant cell granuloma of the jaws. *Oral Surgery Oral Medicine Oral Pathology Oral Radiology & Endodontics*, 81:720, 1996
14. Kermer C, Millesi W, Watzke IM: Local injection of corticosteroids for central giant cell granuloma. A case report. *International Journal Maxillofacial Surgery*, 1994;23:366-368.
15. Kramer IRH, Pindborg JJ, Shear M: *Histological Typing of Odontogenic Tumors*. 2nd Edn.; Springer-Verlag, Berlin 1991;pp 31.
16. Liu B, Yu SF, Li TJ: Multinucleated giant cells in various forms of giant cell containing lesions of the jaws express features of osteoclasts. *Journal of Oral Pathology & Medicine*, 2003; 32(6): 367-375.
17. Pogrel MA: Benign Non odontogenic Lesions of the Jaws. In: Peterson's Principles of Oral and Maxillofacial Surgery, (Vol. 1). M Miloro, GE Ghali, PE Larsen, PD Waite (Eds.); 2nd Edn.; BC Decker Inc. London, 2004;pp 597-616.
18. Stewart JCB: Benign Non odontogenic tumors. In: Oral Pathology-Clinical Pathologic Correlations. Regezi JA, Sciubba JJ, Jordan RCK (Eds.); 4th Edn.; Saunders-An Imprint of Elsevier, Philadelphia, 2003;pp289-308.
19. Wang C, Song Y, Peng B, Fan M, Li J, Zhu S, Bian Z. Expression of c-Src and comparison of cytologic features in cherubism, central giant cell granuloma and giant cell tumors. *Oncology Reports*, 2006;15(3):589-594.
20. Wendt FP, Torriani MA, Gomes AP, de Araujo LM, Torriani DD. Intralesional corticosteroid injection for central giant cell granuloma: an alternative treatment for children. *Journal of Dentistry for Children*, 2009; 76(3): 229-232.
21. Whitaker SB, Waldron CA. Central giant cell lesions of the jaws. A clinical, radiologic, and histopathologic study. *Oral Surgery Oral Medicine and Oral Pathology*. 1993;75(2):199-208